

International Atomic Energy Agency Scientific Forum

A Decade of Action on **Cancer Control** and the Way Forward



17 – 18 September 2019
Vienna International Centre
Board Room D, C Building, 4th Floor

Medical imaging technologies and
advances in nuclear medicine
and radiology

Marie-France Bellin

IRSN

INSTITUT
DE RADIOPROTECTION
ET DE SÛRETÉ NUCLÉAIRE



Technical innovations in existing modalities


- Increased resolution and contrast
- 3D imaging, 3D printing
 - Functional imaging
 - Diffusion imaging

Developments in interventional radiology

- Percutaneous ablation of tumors
 - Endovascular treatments

New imaging modalities

- PET-CT
- PET-MR

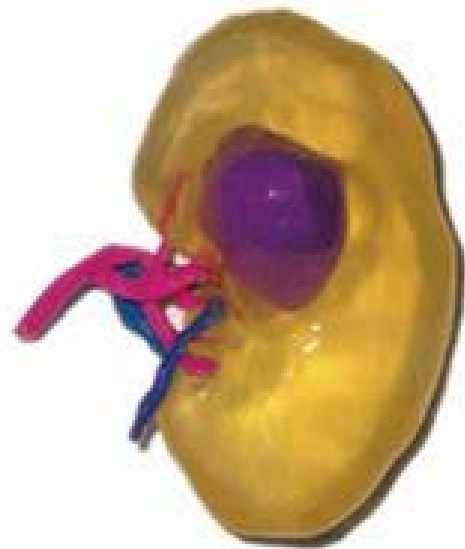
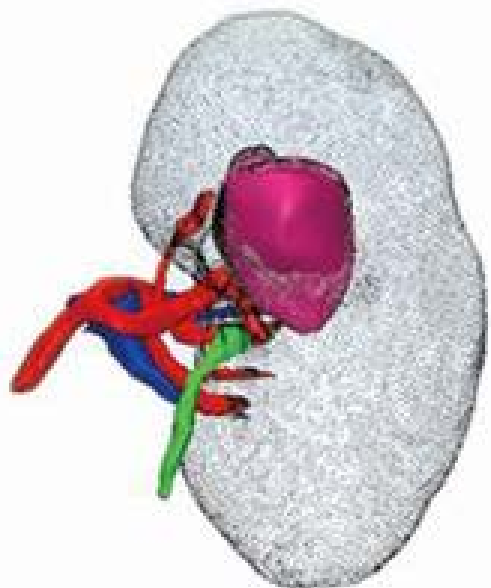
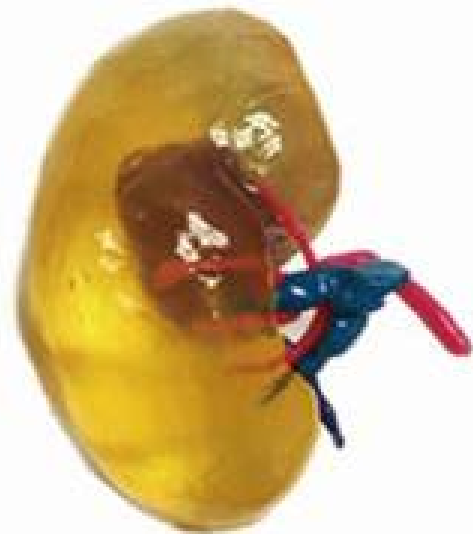
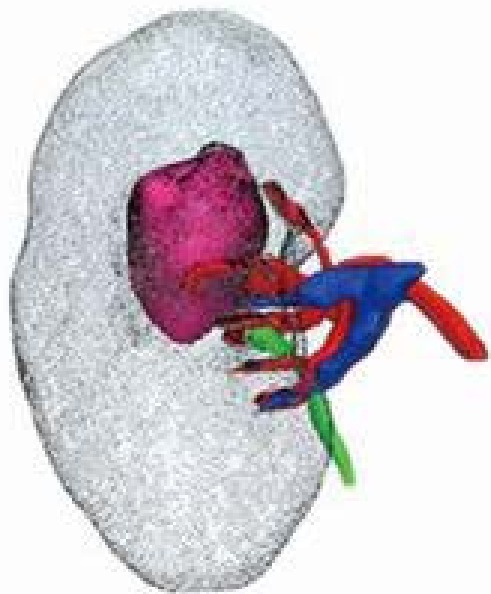
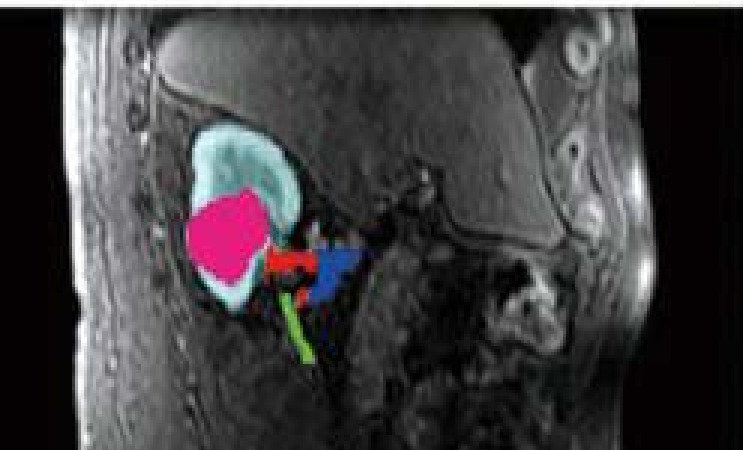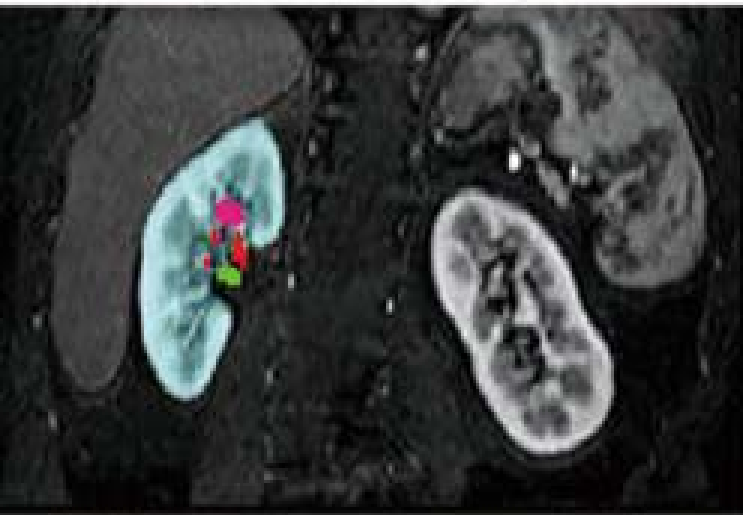
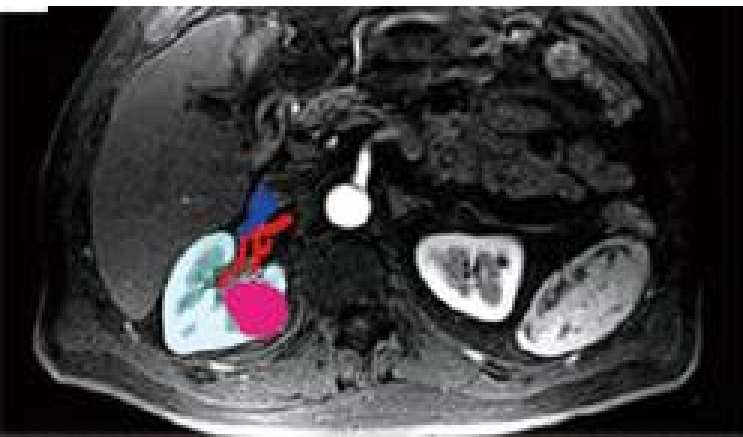- 
- **More precise examinations**
 - **Anatomical and functional information**
 - **Decreased examination times**
 - **Diagnosis, treatment and communication**

Integration of images into imaging networks

Radiomics

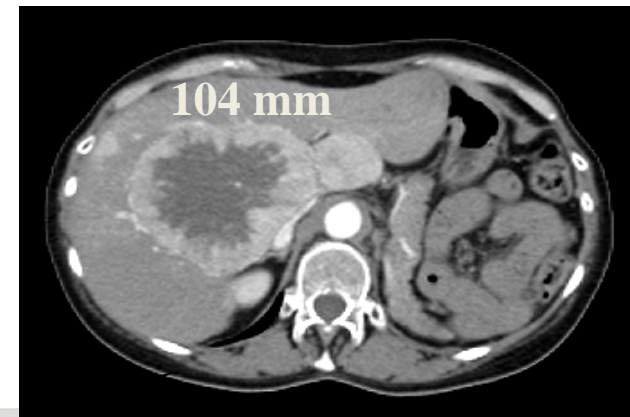
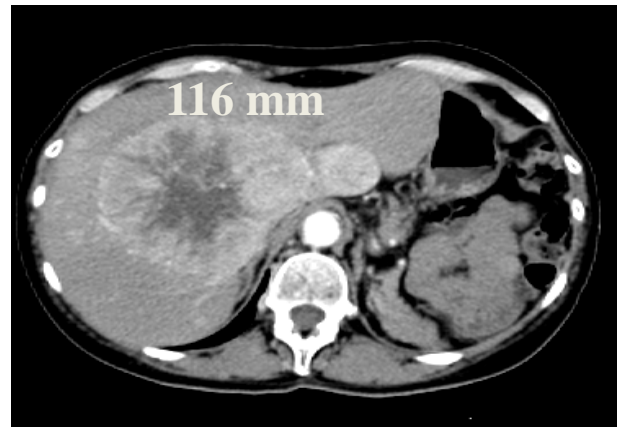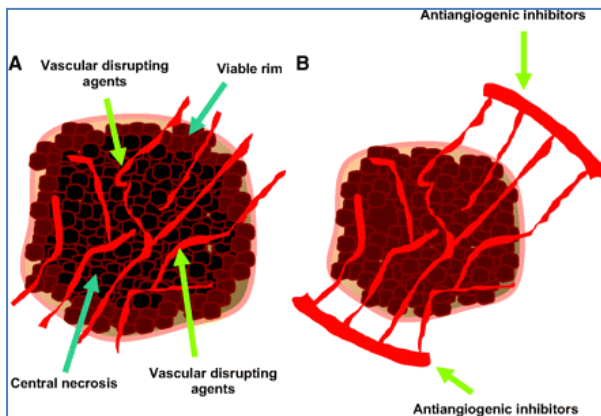
AI...





Functional imaging studies

- To assess response to targeted and immune therapies
- Work by targeting the cancer's specific genes, proteins, or the tissue environment that contribute to cancer growth and survival
- Starve the tumor by keeping new blood vessels from forming
- Drugs cytostatic rather than cytotoxic, produce tumor necrosis



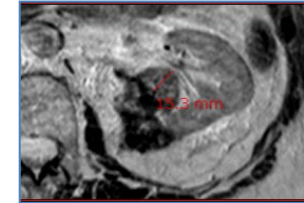
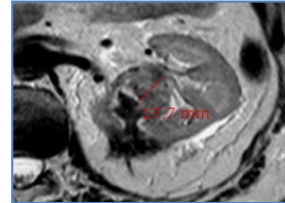
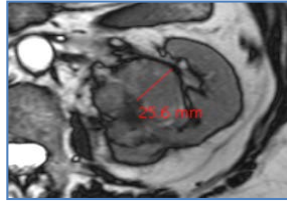
- **size criterion?**



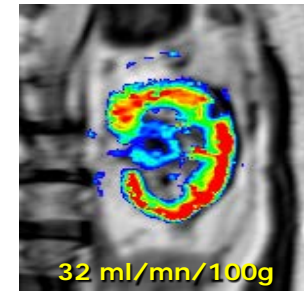
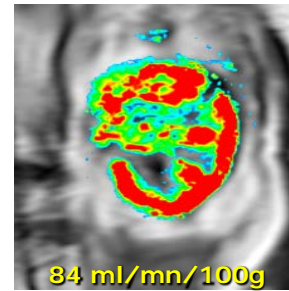
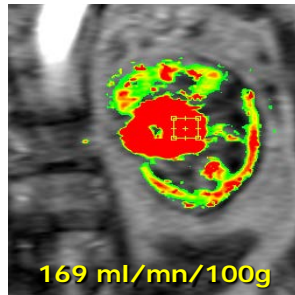
29-01

25-04

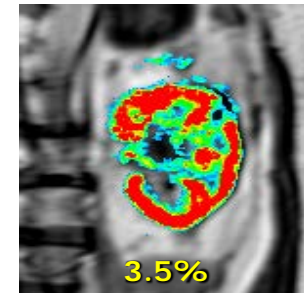
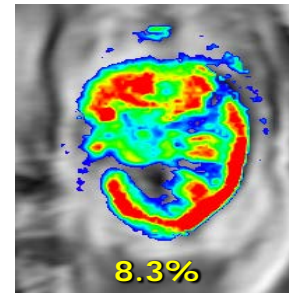
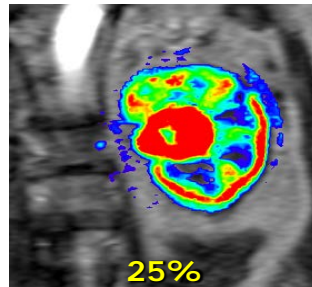
25-07



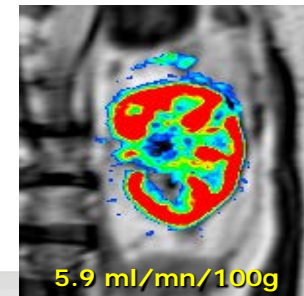
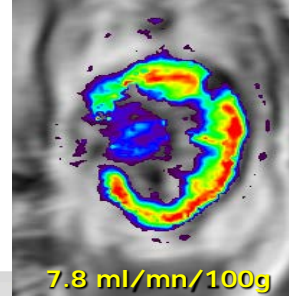
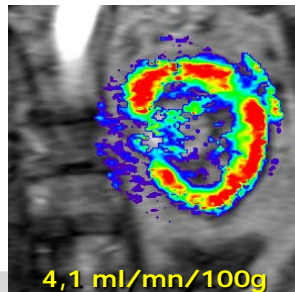
**Blood
flow**



**Blood
volume**



**Capillary
permeability
K-trans**

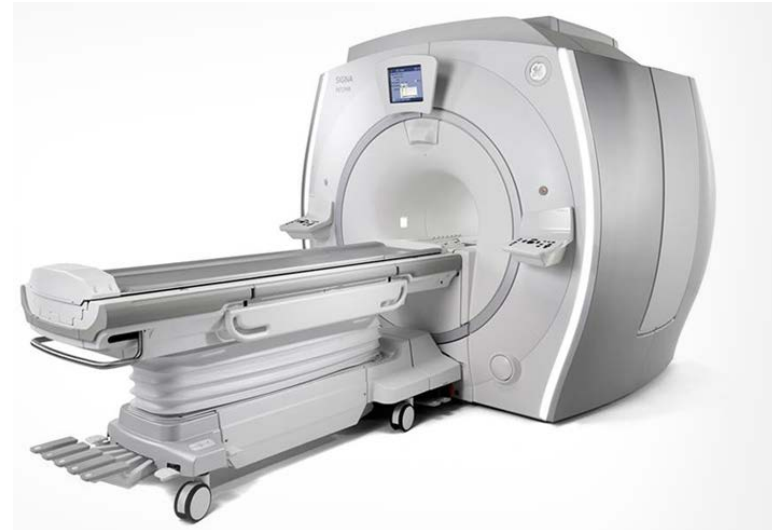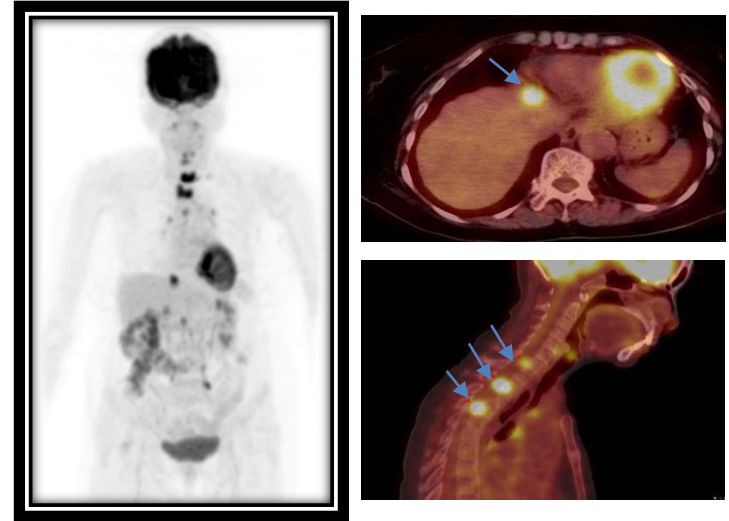


Courtesy N. Grenier



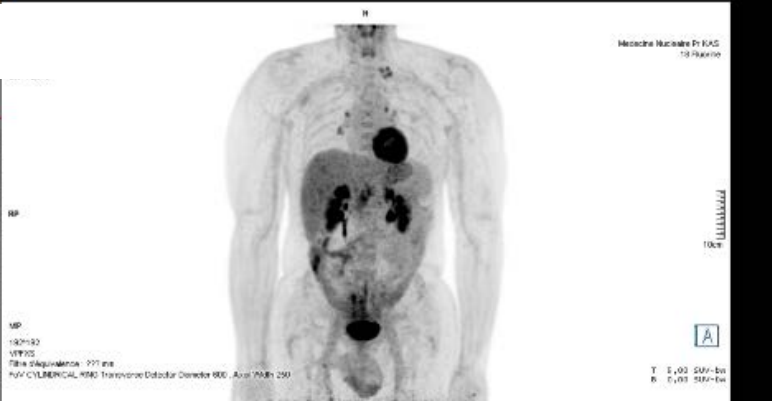
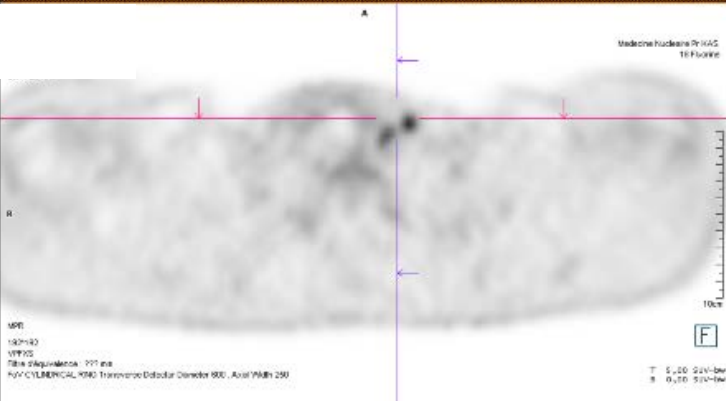
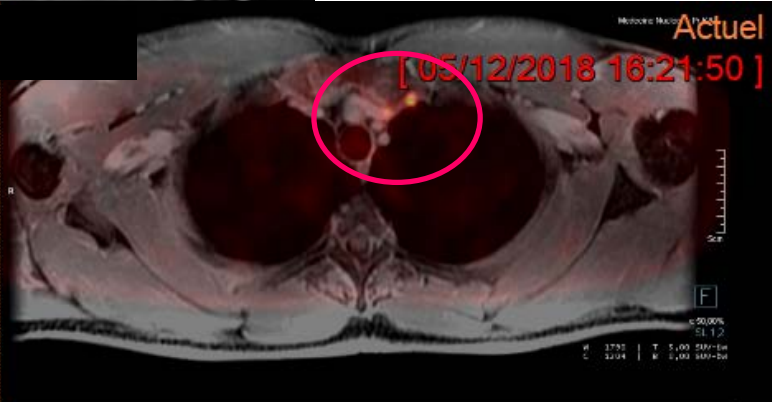
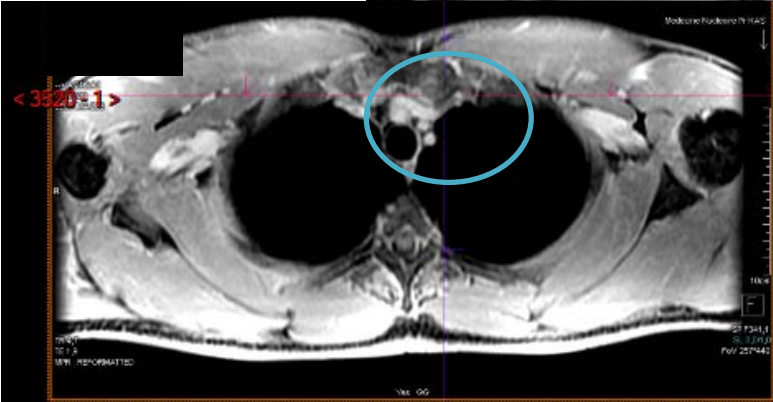
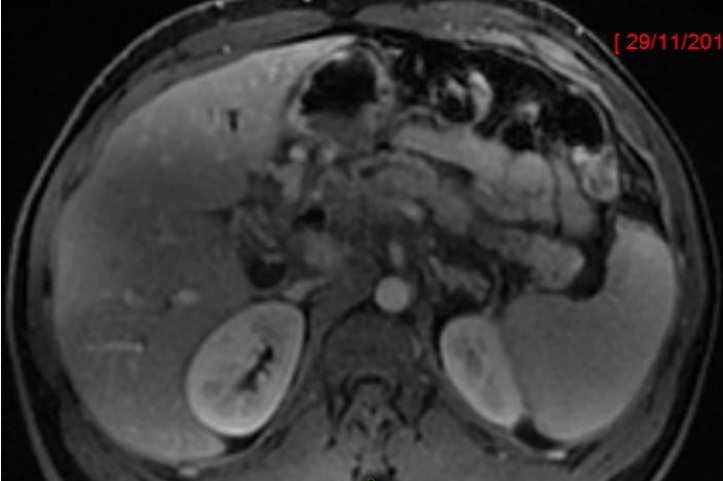
New imaging modalities : PET-CT and PET-MR

- PET-CT: pivotal role in cancer imaging, new pharmaceuticals
- PET-MR still in evaluation
- Selected indications
- Cost, availability



Reviewer and Modality	N Staging (%)		
	Sensitivity	Specificity	Accuracy
Reviewer 1			
PET/MR imaging	40.0 (4/10)	100 (3/3)	54 (7/13)
PET/CT + MDCT	10.0 (1/10)	100 (3/3)	31 (4/13)
<i>P</i> value	.250	NA	.250
Reviewer 2			
PET/MR imaging	40.0 (4/10)	100 (3/3)	54 (7/13)
PET/CT + MDCT	10.0 (1/10)	100 (3/3)	31 (4/13)
<i>P</i> value	.250	NA	.250

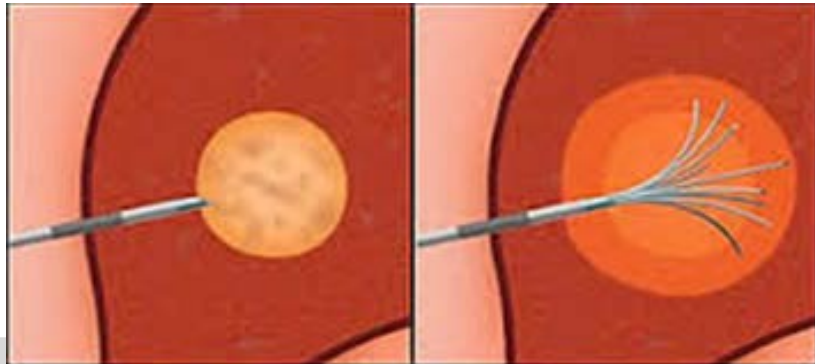
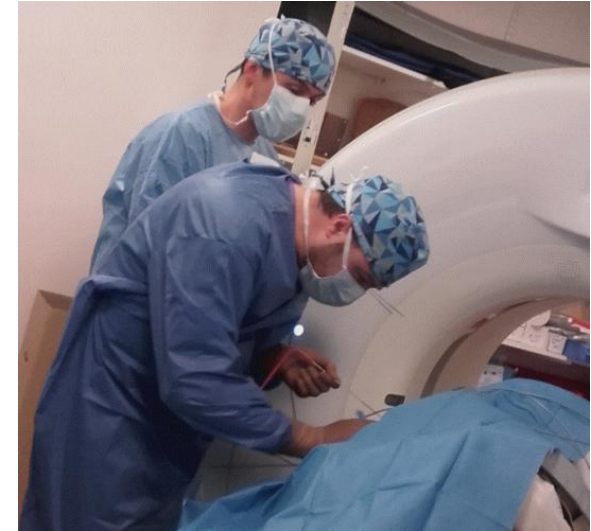



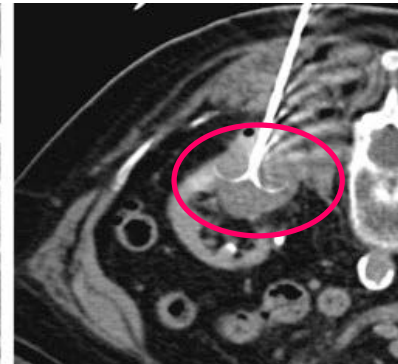
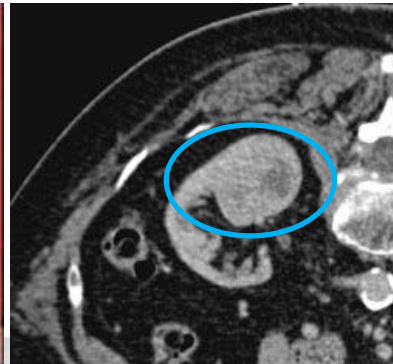
Interventional radiology

Percutaneous ablation of tumors

- Late 1990's, RF, cryotherapy, MW destruction
- Skin incision, local anaesthetic ± sedation
- Treatment time ~60 min, repeat procedures, speedy recovery, minimal complications
- Liver, kidney, lung, bone, adrenals, pancreas
- Not surgical candidates, first-line treatment
- Surgery and chemotherapy avoided



About cancer.com



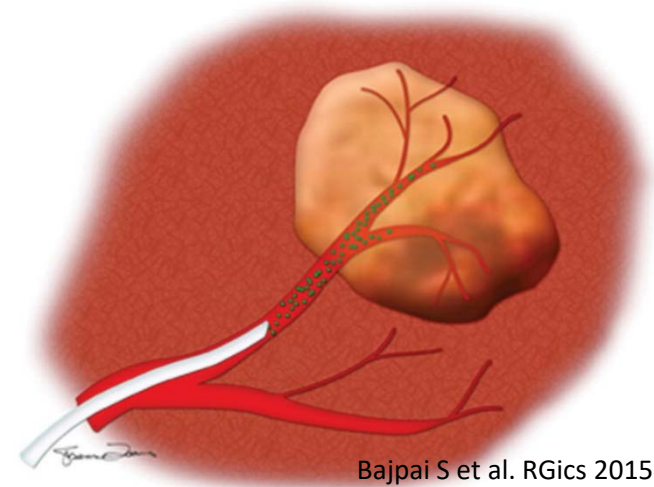
Courtesy F. Cornelis



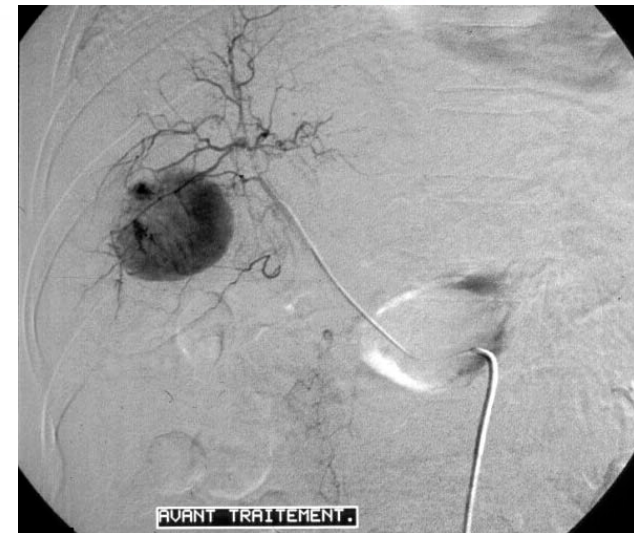Interventional radiology

Chemo/radioembolization

- Targeted therapy into arterial blood vessels supplying the tumour
- TACE (transarterial chemoembolization) or TARE (uses microspheres impregnated with ^{90}Y)
- Primary and secondary hepatic tumors
- Outpatient basis, advanced, bridge to transplantation



Bajpai S et al. RGics 2015



Perspectives

- Imaging plays an increasing role in the management of cancer patients (multidisciplinary, personalized medicine, AI)
- Innovations are beneficial to patients. Because of increased survival rates and increased use of diagnostic and interventional procedures radiation exposure is a concern
- There is a need for specific attention to radioprotection of patients and health workers. This justifies special attention to IAEA/WHO joint position statement (Bonn Call for Action): justification, optimization, etc.
- IRSN is committed to participating in research in this area through national and international programs (Euramed)

