



IAEA

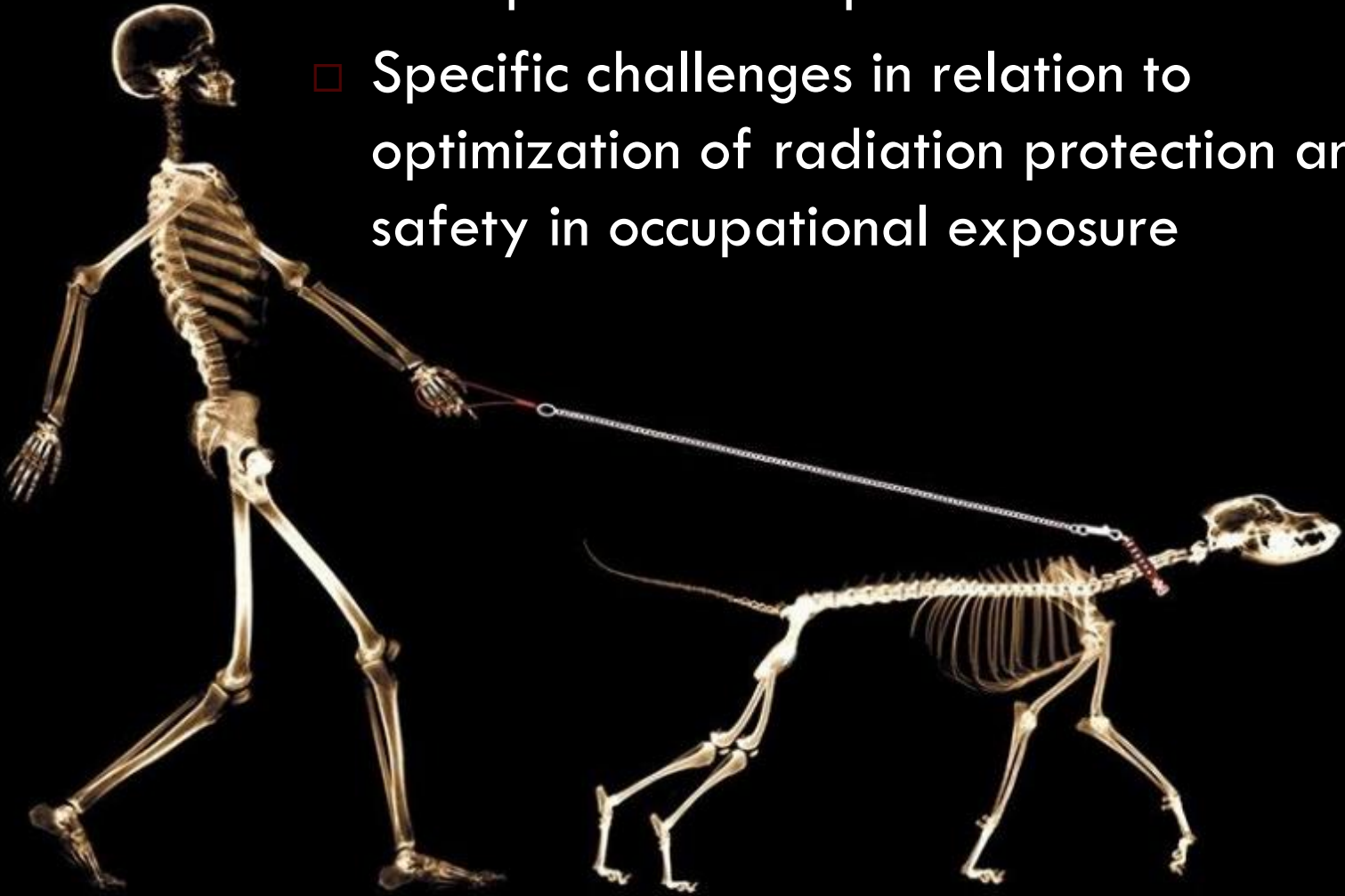
International Atomic Energy Agency

62nd Regular Session of the IAEA General Conference
Senior Regulators' Meeting – September 20th 2018

USING IONIZING RADIATION IN VETERINARY PRACTICE FOR DIAGNOSIS AND THERAPY

Dr. Jérôme Benoit, Dip ACVR-Radiation Oncology
France

- Increased demand in veterinary medicine
- Use of more advanced diagnostic and therapeutic techniques
- Specific challenges in relation to optimization of radiation protection and safety in occupational exposure



Alongside with the « humans »

- X-Rays (Roentgen 1895)
- 1896 – 1st papers Veterinary Radiology
- 1905 – Veterinary Studies presented at Congress
- 1939 – *The Veterinary Student*

The Significance of the X-Ray in Veterinary Medicine

RUSSELL BEAMER

IN THE years between the announcement of their discovery by Wilhelm Konrad Roentgen, on December 28, 1895, and the present, x-rays have contributed greatly in advancing medical knowledge. In internal medicine, surgery and dentistry these rays have been of very great value in the practice of veterinary medicine as a diagnostic aid but until recently their importance and value in the practice of veterinary medicine and surgery have been little appreciated. Trained veterinary scientists, unfortunately, have made no concerted effort to apply x-rays in the study and diagnosis of animal pathology. It is the firm conviction, however, of those who have engaged in this work that its importance and value will increase as more experience is gained. The veterinary profession of recent years has become x-ray conscious and rightfully so, as there is an important, necessary, useful field for its use in veterinary medicine. However, the use of the x-ray is not entirely without its hazards.

Hazards

There are two "hazards" commonly associated with the operation of x-ray equipment, one being **electrical shock**, and the other the damage done as the result of



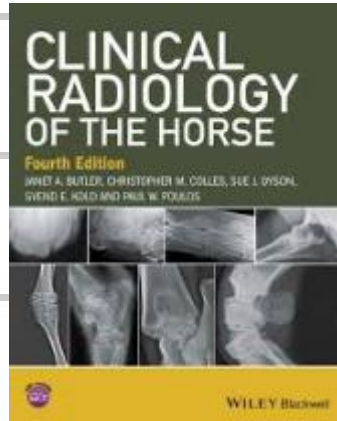
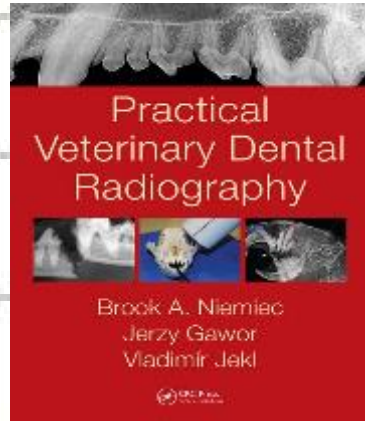
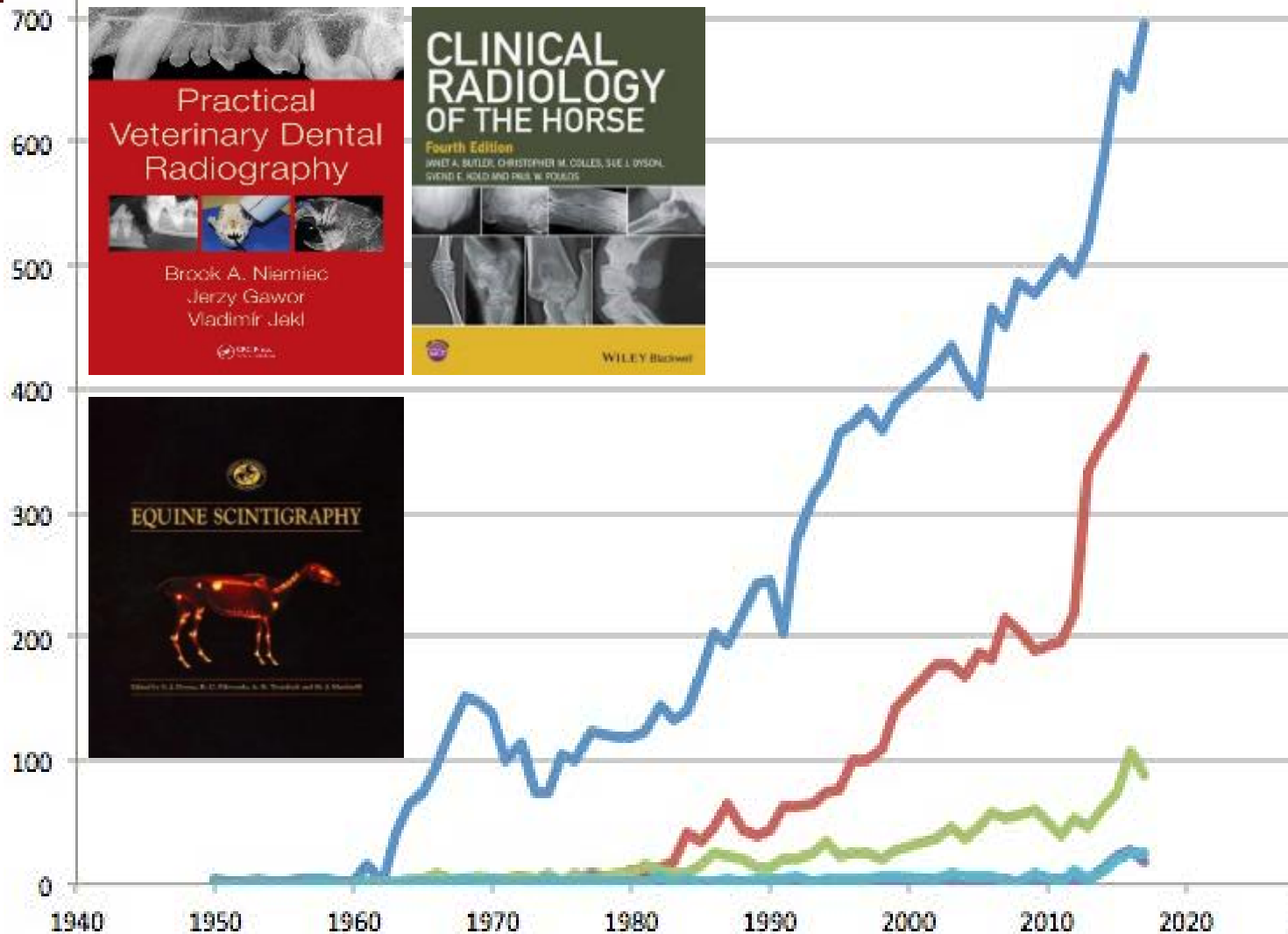
cumulative effects of x-ray on the body tissues. The first danger may occur due to the necessity for high voltage at the x-ray tube for the production of x-radiation.

The other hazard—a very important one, especially to the small animal practitioner—arises from the absorption of x-radiation by the operator, patient, or anyone else in its field of influence; and, because its effects are not apparent immediately after exposure takes place, it becomes necessary to have a complete understanding of what it is and the precautions necessary for adequate protection.

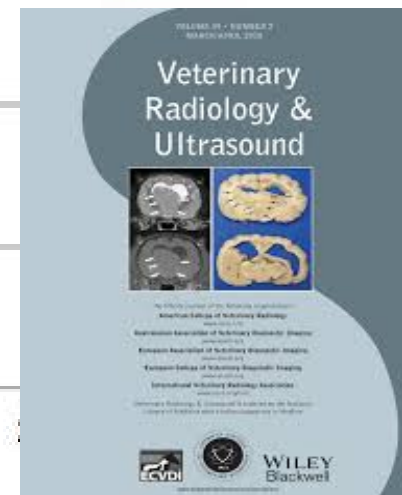
Effects

The physiological effects of x-ray are dependent, among other things, upon the cumulative absorption over a given period. Fortunately, however, the living body is capable of throwing off these effects if the total quantity absorbed within a given time is not too great. Whether by cumulative absorption or from continuous exposure, an overdose of x-ray produces blood changes, loss of hair, malignancies, malfunction of internal organs, erythemas, and the like, the latter usually referred to as "x-ray burns". The first manifestation of too much exposure to a given part may be a loss of hair or reddening.

Pubmed Trends / Literature



- Radiology
- Nuc Med
- RadioTherapy
- Interventional Rx
- RP



Radiology / RO Training

- Recognised Specialists Training
 - 1961 ACVR (x267)
 - 1992 ACVR-Radiation Oncology (x70)
 - 1994 ECDVI (x292)
 - 2014 ECDVI-RO (x7)

- Societies (5 continents)
- Other Specialties: Dentistry, Orthopedics, Neurology, Oncology

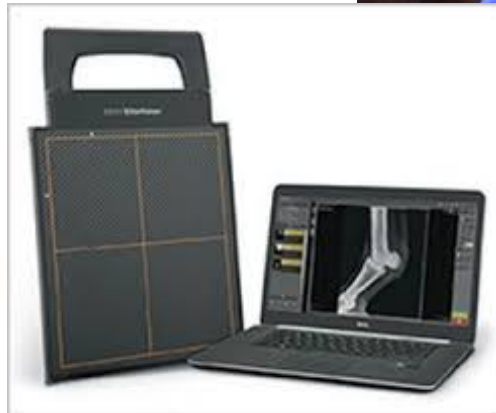
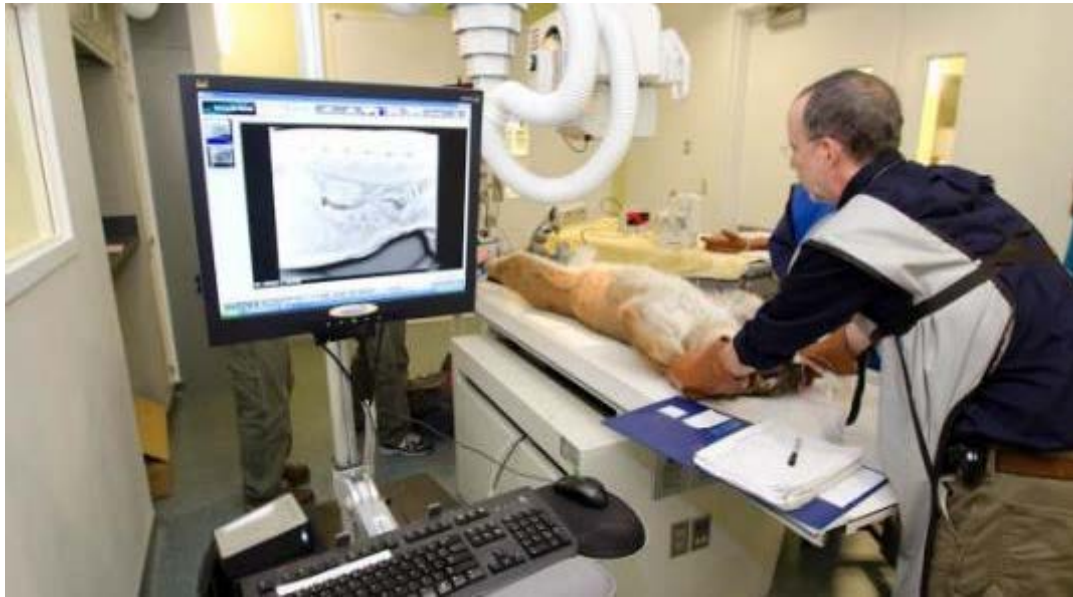
Veterinary World

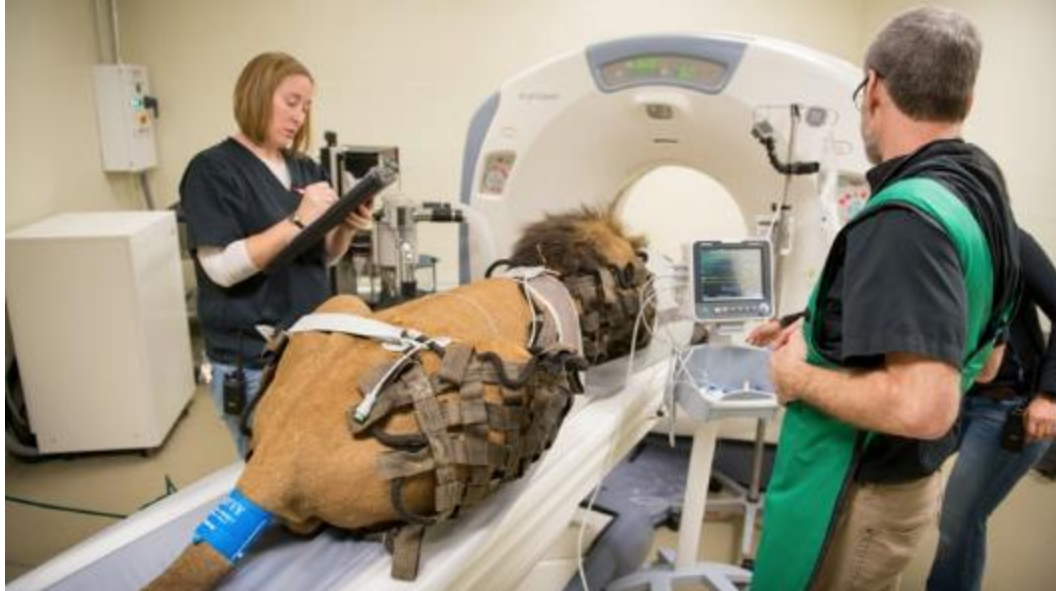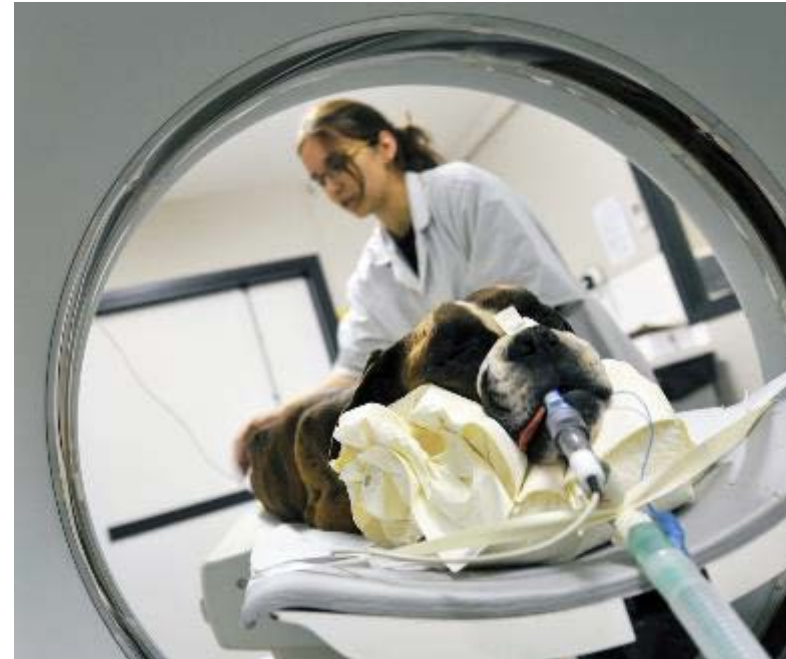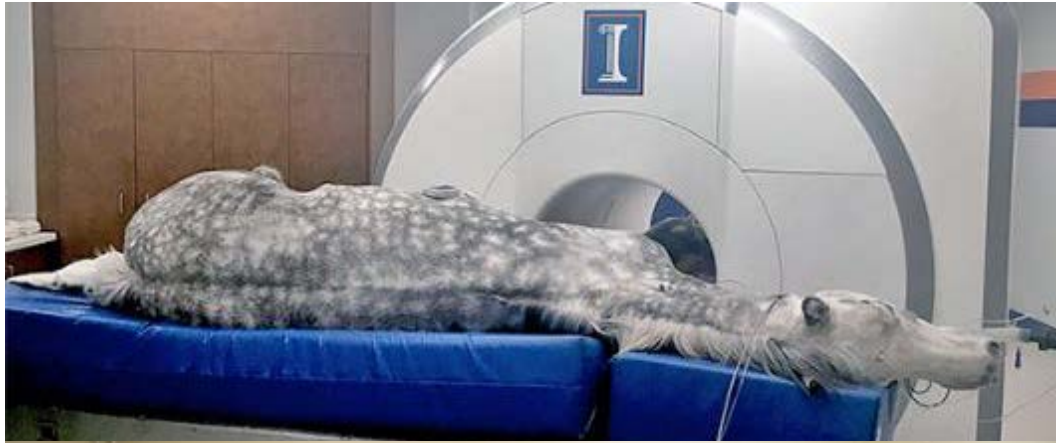- Academic institutions (variable equipment)
- Large Private Networks (all possible equipment)
 - US, UK, EU
- Independent clinics and hospitals (radiology suite +/- CTs)
 - France, 85% practices (6300) equiped with 1+ Xray

- Teleradiology
- Tele-RT planning

Veterinary Radiology — Everywhere, Everyone



Veterinary Computer Tomography

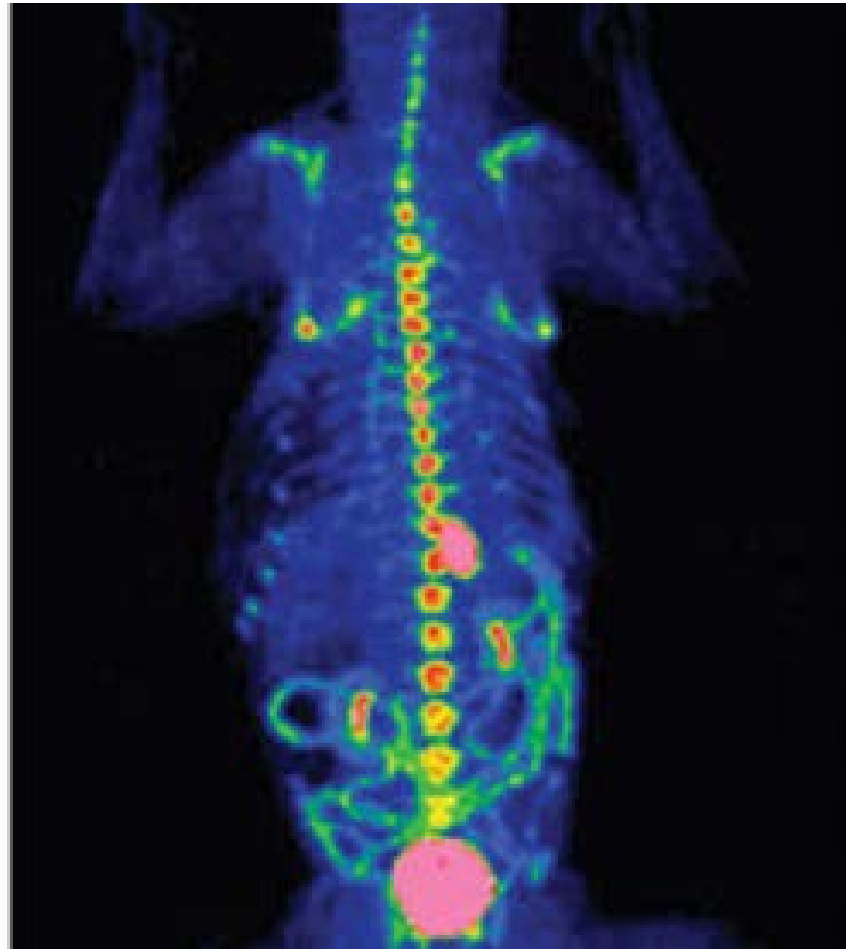
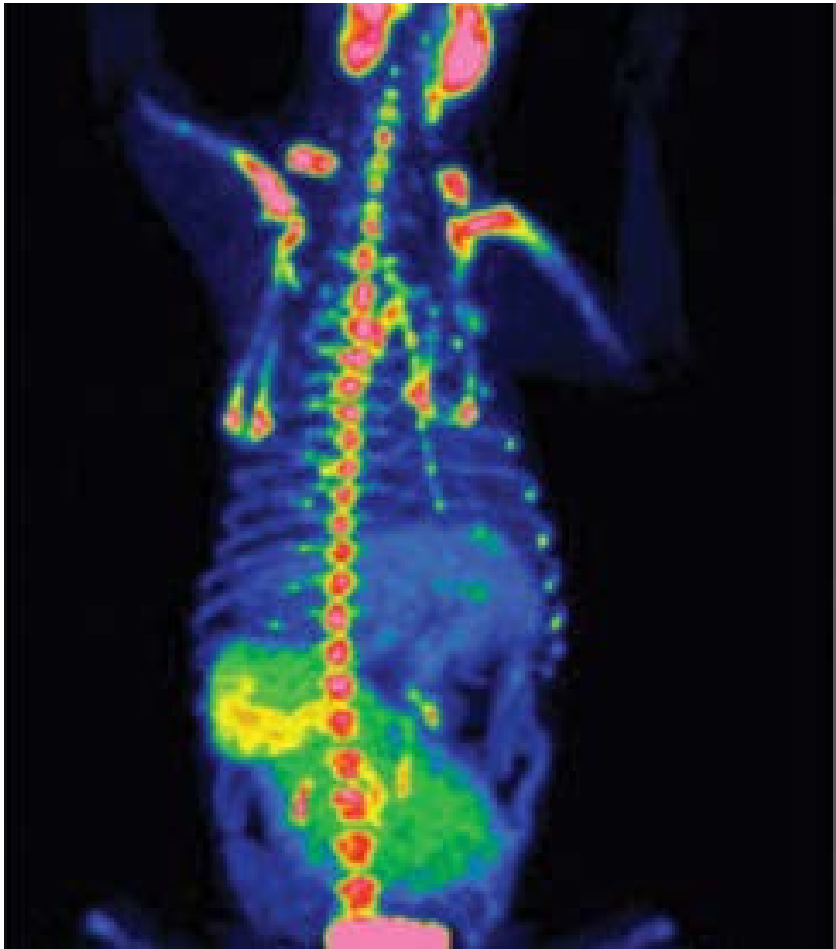


Available +++

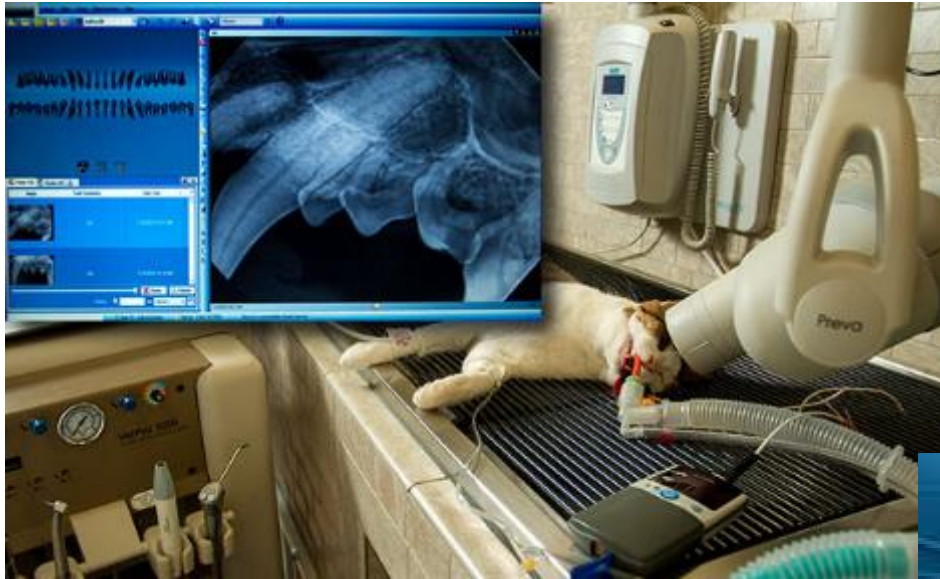2-64 slices CTs

Cone-Beam CTs

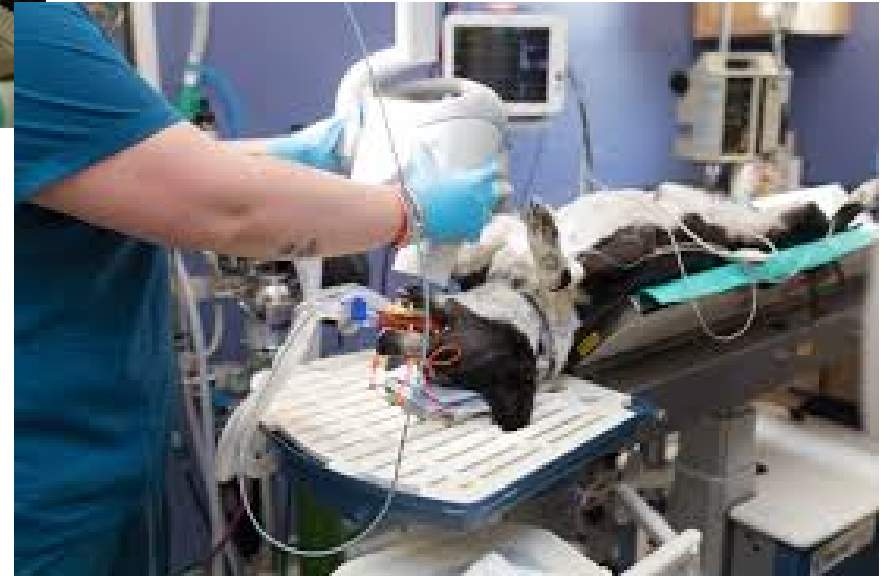Veterinary PET imaging (rare)



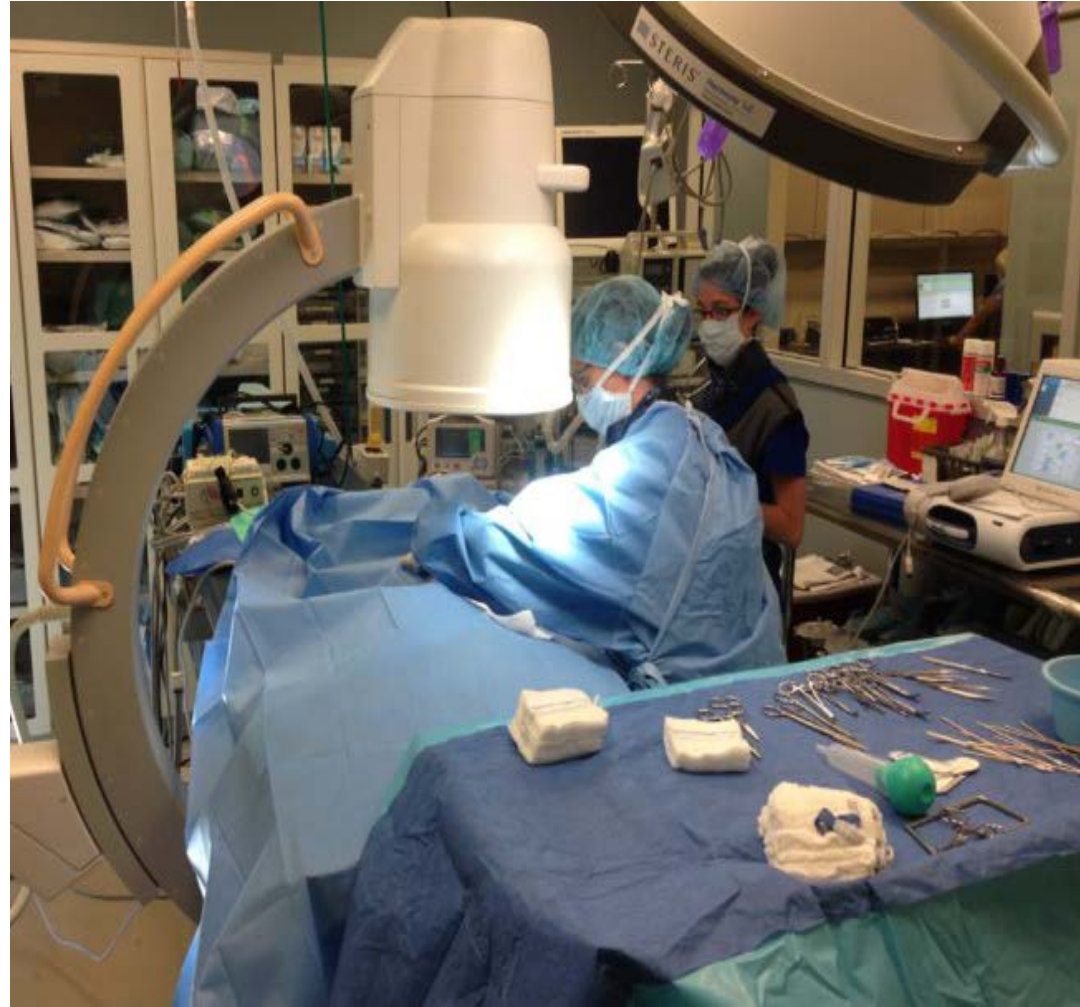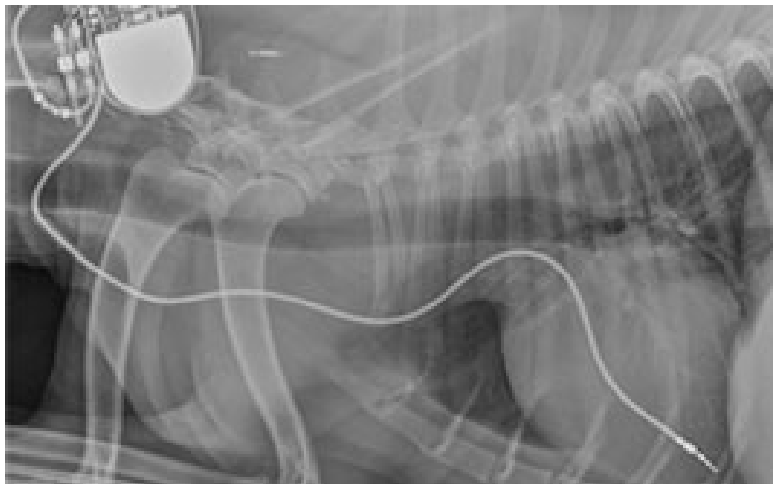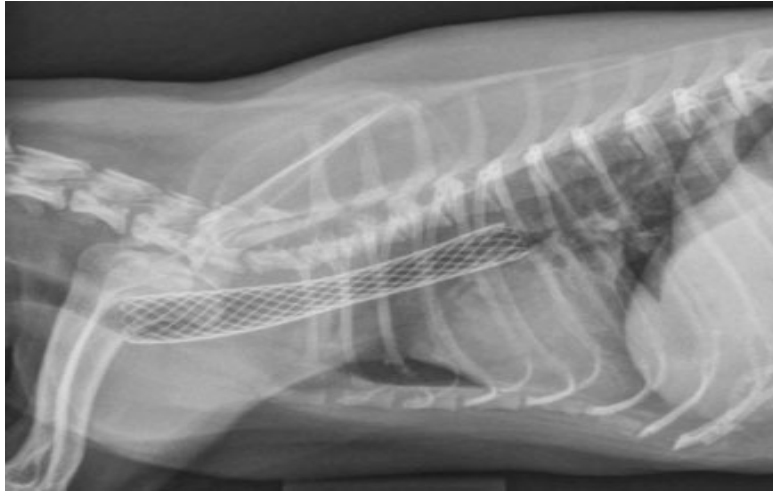
Veterinary Dentistry



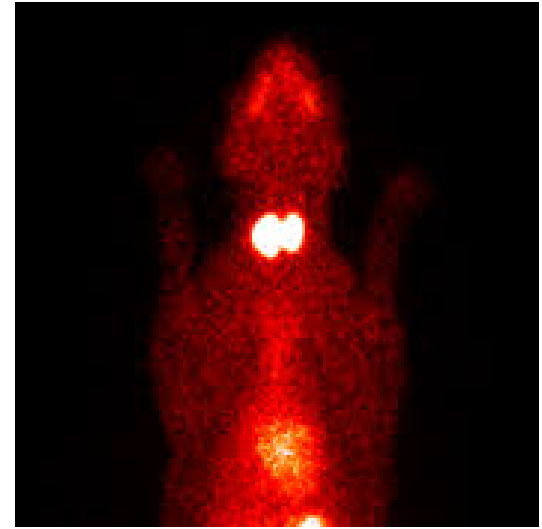
At institutions
with dentistry experts



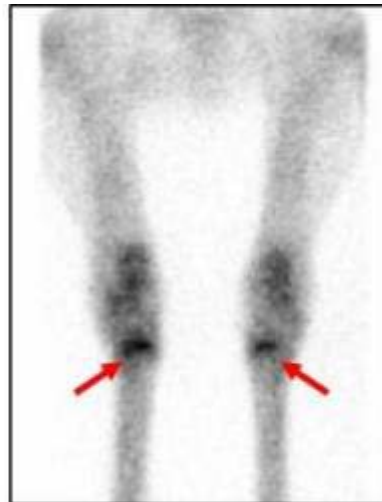
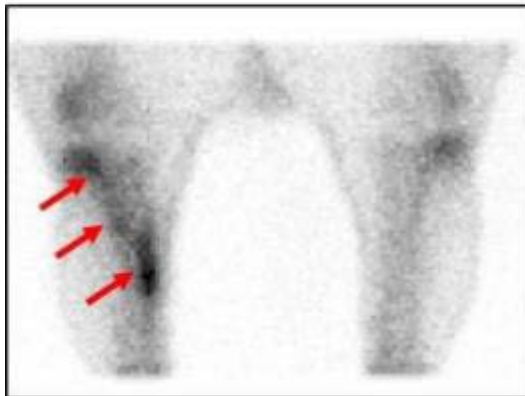Veterinary Interventional Radiology



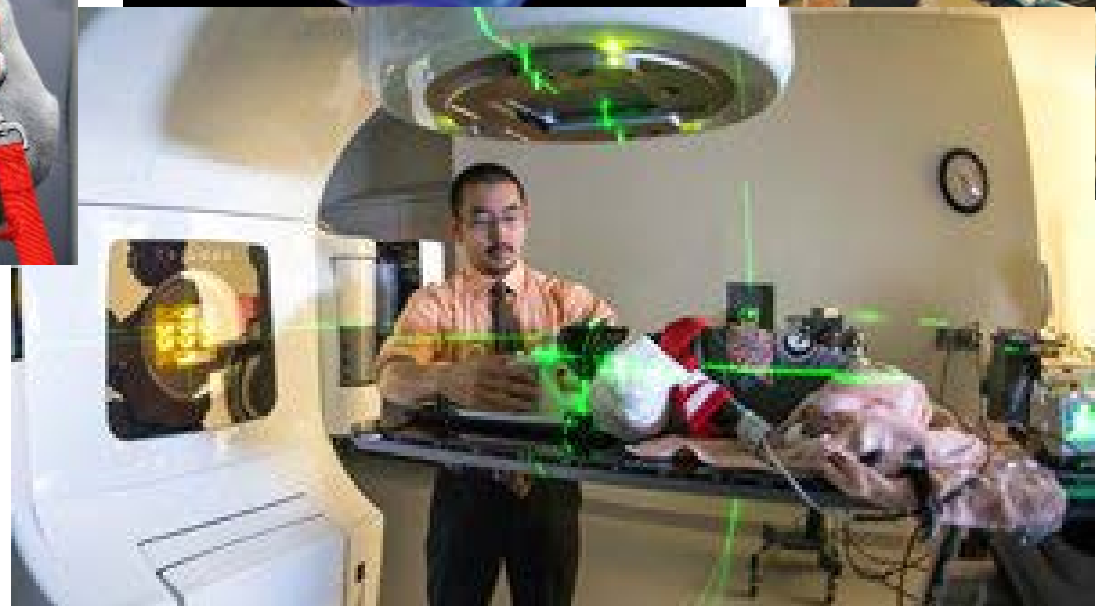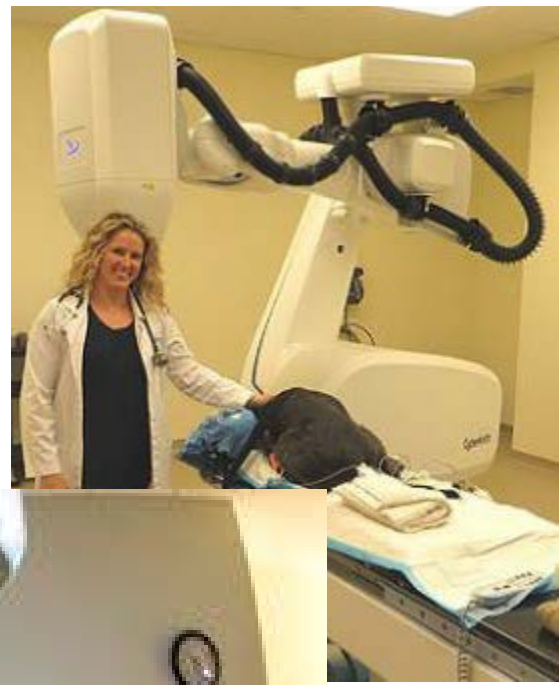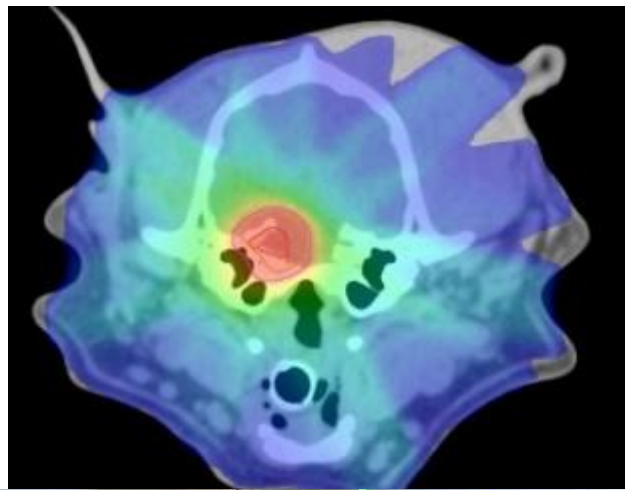
Veterinary Nuclear Medicine



+ Iodine 131
for hyperthyroidism



Veterinary Radiotherapy



40 US/CA
20 EU
+ Australia
+ Japan
+ ...

Questions?

